

Sporotrichosis in Iran: A mini review of reported cases in patients suspected to cutaneous leishmaniasis

Mahmoudi S¹, Zaini F^{2*}

¹ MSc Student of Medical Mycology, Department of Medical Parasitology and Mycology, School of Public Health, Tehran University of Medical Sciences, Tehran, Iran

² Professor of Medical Mycology, Department of Medical Parasitology and Mycology, School of Public Health, Tehran University of Medical Sciences, Tehran, Iran

*Corresponding author: Farideh Zaini, Department of Medical Parasitology and Mycology, School of Public Health, Tehran University of Medical Sciences, Tehran, Iran. Tel: +9802142933137; Email: fzaini@tums.ac.ir

(Received: 5 February 2015; Revised: 25 May 2015; Accepted: 2 June 2015)

Abstract

Sporotrichosis is a chronic subcutaneous fungal infection with global distribution. It is a rare fungal infection with nine reported cases in Iran, including eight humans and one animal, within the past 30 years. Among the human cases, seven were of the fixed cutaneous type of sporotrichosis and one had sporotrichoid lymphocutaneous. The reported patients were within the age range of 23-60 years, and six of them were female. The most frequent sites of infection were forearms and hands, as well as the face and legs. In addition, the majority of the cases had previously been suspected of leishmaniasis and received treatment. Sporotrichosis is not a well-known condition in Iran and is often misdiagnosed and erroneously treated for other cutaneous parasitic or bacterial infections with similar clinical manifestations. Therefore, sporotrichosis should be taken into account in the differential diagnosis of nodular-ulcerative skin lesions.

Keywords: Mycoses, Parasitic disease, Skin, *Sporothrix*, Iran

➤ How to cite this paper:

Mahmoudi S, Zaini F. Sporotrichosis in Iran: A mini review of reported cases in patients suspected to cutaneous leishmaniasis. *Curr Med Mycol*. 2015; 1(2): 39-45. DOI: [10.18869/acadpub.cmm.1.2.39](https://doi.org/10.18869/acadpub.cmm.1.2.39)

Introduction

Sporotrichosis is a chronic fungal disease causing cutaneous and subcutaneous nodular lesions and involvement of the lymph nodes [1]. This infection is widespread worldwide, particularly in temperate and tropical regions; countries such as Mexico, Uruguay, Brazil, South Africa, Japan, India and Korea account for the highest rate of sporotrichosis [2, 3].

Sporotrichosis mostly impacts the skin and subcutaneous tissues, while in some cases, it could disseminate and involve other organs as well [4]. Moreover, both genders and all age groups are equally affected by sporotrichosis, and the highest prevalence is observed among gardeners, farmers, florists and the like [5]. Traumatic inoculation of fungi in the skin is usually preceded by the clinical manifestations of sporotrichosis [1]. In addition to human and animal involvements, there are several reports of zoonotic transmission of sporotrichosis to humans [6-13].

Although *Sporothrix schenckii* has been known as the single etiologic agent of sporotrichosis for many years, recent studies have

indicated other species of *Sporothrix* genus, including *S. globosa*, *S. brasiliensis*, *S. mexicana*, *S. luriei*, *S. pallida* (formerly *S. albicans* and *S. nivea*) and *S. schenckii sensu stricto* to be the main agents of this disease [14-17].

Since the lesions caused by sporotrichosis may vary in appearance or become crusty, they need to be differentiated from other cutaneous diseases such as leishmaniasis, chromoblastomycosis, tuberculosis, sarcoidosis and lupus vulgaris. The present review aimed to evaluate the cases of sporotrichosis (eight humans and one animal) reported during 1984-2014.

Reported Patients

Case One

The first case of sporotrichosis was diagnosed by Zaini in 1983 [18] in a 36-year-old female patient presented with chronic subcutaneous lesions on her right forearm. Initially, the lesions had appeared as small nodules resembling insect bites and gradually transformed into ulcerated lesions. After two surgical excisions within eight months, the

lesions were diagnosed as leishmaniasis and treated with glucantim, however, there was no progress in the treatment process (Figure 1).

Furthermore, aspirated exudate and pus-filled lesions were studied in the direct examination with potassium hydroxide (KOH) and cultures on Sabouraud agar (S), Sabouraud chloramphenicol cycloheximide agar (SCC), blood agar (BA) and brain-heart infusion (BHI) agar at temperatures of 26°C and 37°C, respectively.

Direct examination was negative for fungal elements, and no diagnosis could be achieved through several biopsies of different sections; however, mycelial form of *S. schenckii* was detected in the cultures at 26°C.

Eventually, diagnosis of sporotrichosis was confirmed after the observation of colony pigmentation, microscopic evaluations of the mycelial form, yeast transformation at 37°C and detection of single, budding yeast-like cells in different forms and sizes (Figure 2). The patient received treatment with saturated potassium iodide (KI) for three months and the lesions were healed completely.

Case Two

In the same year (1983), the second case of sporotrichosis was diagnosed by Nematian [19] in a 60-year-old female patient presented with ulcerated lesions on the left lower leg (Figure 3). The patient was referred to Medical Parasitology, Bacteriology and Mycology laboratories of the School of Public Health at Tehran University of Medical Sciences for the diagnoses of leishmaniasis, tuberculosis and fungal infections.

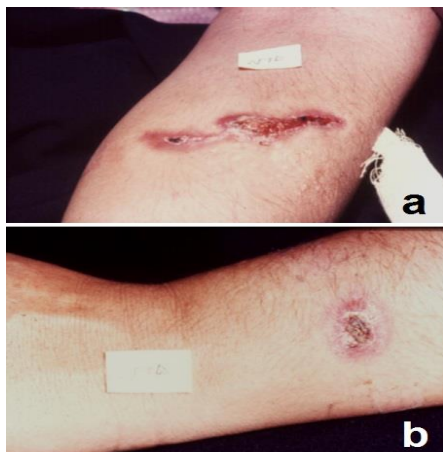


Figure 1. a & b: Fixed cutaneous sporotrichosis on forearm at first admission after two surgical excisions in the patient suspected of leishmaniasis (Case no. 1)

Furthermore, the patient had a misdiagnosis of leishmaniasis and two consecutive treatments with glucantime without recovery.

Lesion scraping and tissue biopsy were performed for laboratory diagnosis. Although direct examination with KOH was negative, tissue sections stained with hematoxylin-eosin (H&E) and periodic acid-schiff (PAS) revealed asteroid bodies. In addition, cultures were performed using S, SCC, BA and BHI agar media and incubated at 25°C and 37°C, respectively.

Diagnosis of sporotrichosis was established based on the macroscopic and microscopic characteristics of the mycelial colony, thermal dimorphism, orchitis followed by the inoculation of fungi on guinea pig testicles, observation of cigar-shaped yeast cells in stained tissue sections of testicles and isolation of *Sporothrix* by testicle tissue inoculation in the culture medium. The patient received treatment with KI for three months and completely recovered.

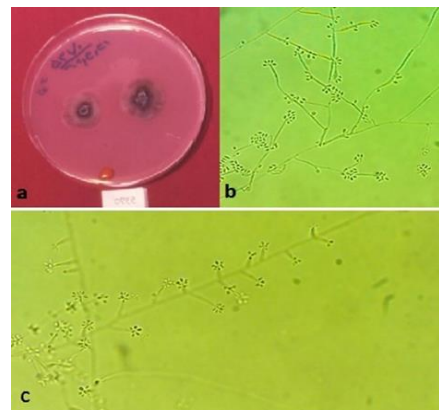


Figure 2. Macroscopic (a) and microscopic (b & c) feature of mycelial form of *S. schenckii* isolated from Skin Lesions

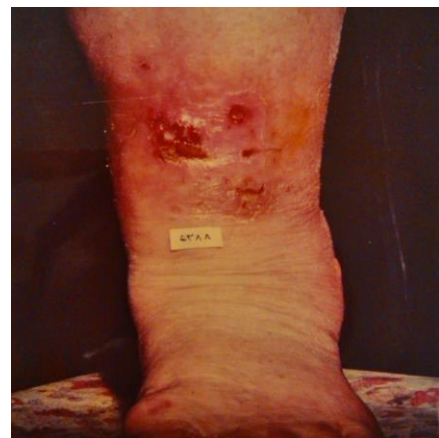

Figure 3. Ulcerative lesions of the left lower leg at first admission (Case no. 2)

Cases Three & Four

Two cases of sporotrichosis in patients suspected of cutaneous leishmaniasis were diagnosed by Dehghan in 1987 [20]. The first case was a 50-year-old female patient presented with a lesion on the right forearm and a growing small lesion similar to insect bites, which had appeared within the past 45 days and gradually transformed to an ulcerated lesion (Figure 4). The second case was a 24-year-old male patient presented with two raised skin lesions with drainage and pus on both elbows (Figure 5). Moreover, the patient had a small, painless, purulent lesion during the year before.

Both cases were negative for leishmaniasis and after parasitological tests, were admitted to medical mycology laboratory of School of Public Health at Tehran University of Medical Sciences.

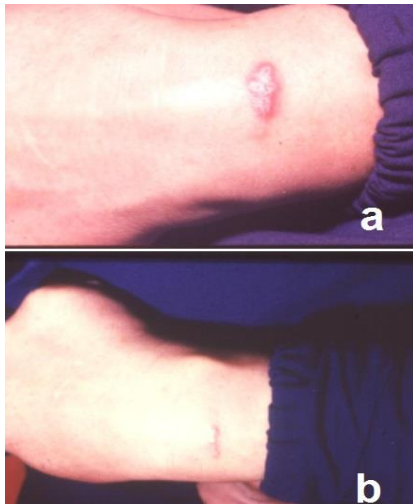


Figure 4. Forearm lesion before (a) and one month after treatment (b) with KI (Case no.3)

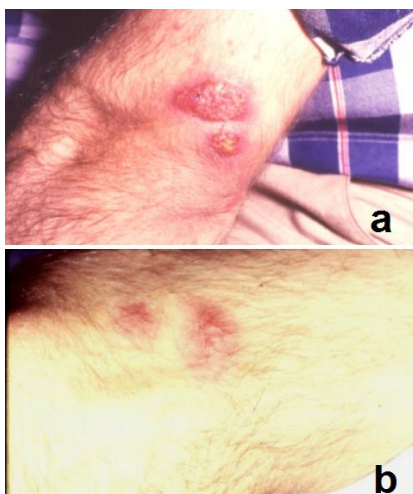

Figure 5. Elbow lesions before (a) and one month after treatment (b) with KI (Case no.4)

Furthermore, mycological examinations were performed on the exudate and pus of lesions, and KOH direct examination was negative in the second patient, while a few tubular budding yeasts were detected in the first patient.

Diagnosis of sporotrichosis was established based on the isolation of *S. schenckii* in S and SCC media at 26°C, ability of yeast cell formation in BHI and brain-heart infusion blood (BHIB) media at 37°C, detection of cigar-shaped yeast cells in the infected organs of the inoculated mice (*Mus musculus*) and growth of *Sporothrix* from samples of these organs in the culture medium (Figure 6, 7).

The achieved diagnoses were confirmed by API 20C Auxanogram and latex agglutination test (LAT) performed on the serum of the patients in order to identify anti-*Sporothrix* antibodies. The patients received treatment with KI for three months and completely recovered.

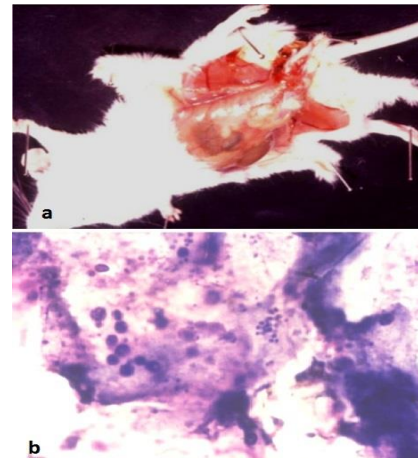


Figure 6. Developed experimental orchitis (a) and *S. schenckii* yeast cells in peritoneal fluid smear (b) of inoculated mice (Giemsa stain×1000)

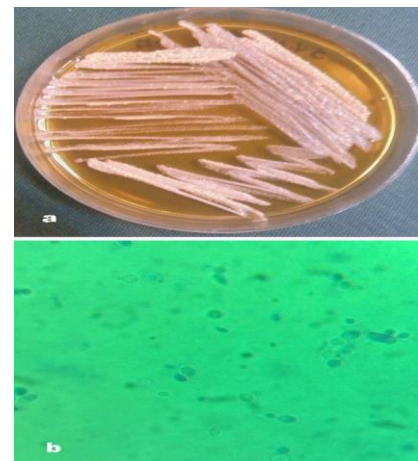


Figure 7. Macroscopic (a) and microscopic (b) feature of *S. schenckii* in yeast form, teased mount in Lactophenol cotton blue

Case Five

The first case of lymphocutaneous sporotrichosis in Iran was reported by Moghadami and Adimi in 1988 [21] in a 55-year-old male patient presented with a history of injury in the left index finger. A few years after this injury, the patient had been referred to the Medical Parasitology, Bacteriology and Mycology laboratories of the School of Public Health at Tehran University of Medical Sciences for the diagnoses of leishmaniasis, tuberculosis and fungal infections.

At the time of admission, the patient had several nodular and ulcerated lesions on the lymphatic vessels of the left hand. Although stained tissue sections with H & E and PAS were negative for fungal elements, cultures on S, SCC and BA media at 25°C were positive. Furthermore, *S. schenckii* elements were identified based on the microscopic characteristics of the mycelial form, colony pigmentation on corn meal agar (CMA), thermal dimorphism on BHI agar at 37°C and observation of asteroid bodies and cigar-shaped yeast cells in tissue sections of inoculated testicles of hamster.

Case Six

The first case of sporotrichosis arthritis in Iran was reported by Asadi et al. in 1997 [22] in a 36-year-old female patient presented with a history of pain and swelling in the right knee for the past three years. Despite regular referrals to health care centers and prescription of various medications for brucellosis, tuberculous arthritis, osteoarthritis and synovial fluid drainage, the patient could not recover.

Finally, two consecutive samples of the synovial fluid were sent to the Medical Mycology Laboratory of Kashan University of Medical Sciences, Kashan, Iran for mycological examinations, and KOH direct examination and staining with giemsa and methylene blue were performed as well.

Moreover, cultures on S, SCC and BHI agar at 25°C were negative for fungal elements. Eventually, diagnosis of sporotrichosis arthritis was established after the observation of oval and cigar-shaped yeast

cells in the synovial fluid of the patient, as well as the peritoneal fluid of the mice that received intraperitoneal inoculation (*Mus musculus*). After six months of treatment with ketoconazole, the patient completely recovered [23].

Case Seven

In one study, Ghodsi et al. [24] reported an unusual case of cutaneous sporotrichosis in a 56-year-old female patient presented with eyebrow and forearm lesions in 2000. Facial and limb lesions had initially appeared within the past six months and six years, respectively. Stained smears of the lesions were negative for leishmaniasis, and exudate stained smears and cultures were as well. In addition, biopsy culture and polymerase chain reaction were negative for acid-fast bacilli.

Although stained tissue sections with H & E and PAS were negative for fungal elements, the cultures were positive, and mycelial form of *S. schenckii* was detected in the medium as well. The patient received weekly treatment with fluconazole 150 mg, and the facial lesions completely healed after 4 months. However, limb lesions did not respond to the treatment after six months.

Case Eight

In another study, Kazemi and Razi (2007) [25] described a case of subcutaneous sporotrichosis in Tabriz, Iran in a 23-year-old male gardener and florist presented with several small lesions and a chain of involved nodules in the left upper arm. In addition, the patient had a history of occupational arm injury.

Direct KOH examination was performed on the pus and scales of lesions, and the tissues were cultured in S, SCC and BHI agar and incubated at 25°C and 37°C, respectively. Identification of *S. schenckii* was based on the observation of yeast cells in the direct examination, mycelial form growth at 25°C and cell transformation to the yeast phase on BHI agar media at 37°C. The patient received treatment with KI, and the lesions were healed after three months. In order to avoid lesion relapse, KI treatment continued for another seven weeks.

Animal Case

In one study, Nadalian et al. [26] described the only animal case of sporotrichosis in Iran (Tehran, 1994) in a 4-year-old male, thoroughbred horse presented with the swelling of the left gaskin and nodular lesions, some of which were observed in a linear order. A six-month history of the lesions was detected in the horse, and tissue specimen was obtained via subcutaneous puncture. Yeast cells were identified in tissue section microscopy, and mycelial form colony of *Sporothrix* was detected in the culture. The animal received daily treatment with KI 10 g; however, complete remission could not be achieved after two months.

Discussion

Sporotrichosis is a chronic mycosis with rarely reported cases in Iran. Among human patients, sporotrichosis most commonly occurs within the age range of 23-60 years and has a higher prevalence among women (5 female and 3 male patients in this study). In the present study, six out of nine cases were suspected of leishmaniasis. Among these patients, stained smears were negative for leishman bodies, while positive cultures in all six cases

confirmed the diagnosis of sporotrichosis. Treatment with saturated potassium iodide was successful in the majority of the reported cases.

Most of the patients reviewed in this study could not remember clearly the circumstances under which they had acquired the infection; however, they were able to present a probable history of injuries from thorns or fences in gardens, or exposure to soil and handling potting soil while working.

Direct examination of clinical specimens in KOH, methylene blue and giemsa was performed in all the cases, and the results were positive in only three patients. Furthermore, in four cases (cases 1, 2, 5 and 7) a cutaneous biopsy was performed, and yeast cells were identified in only one case with H&E and PAS stained slides.

According to the data presented in Table 1 and the observations of other authors in previous studies, direct examination of clinical specimens is often unrewarding. Biopsy is also not recommended due to the rapid diffusion of mycosis and difficulty in the identification of asteroid bodies.

On the other hand, isolation of fungi in clinical samples is considered as the most efficient method to establish the diagnosis of

Table 1. Summary of Reported Sporotrichosis Cases in Iran

| Year | Sex | Age | Site of Infection | Type of Infection | Occupation | DE | HP | C | TD | SL | Treatment | Outcome | Reference |
|------|------------|-----|-----------------------------------|-------------------|------------------|----|----|---|----|-----|-----------|-----------|-----------|
| 1983 | F | 36 | Right arm | Fixed cutaneous | Housewife | N | P | P | P | Yes | KI | Recovered | [18] |
| 1983 | F | 60 | Left lower leg | Fixed cutaneous | Housewife | N | P | P | P | Yes | KI | Recovered | [19] |
| 1987 | F | 50 | Right forearm | Fixed cutaneous | Waiter | P | NP | P | P | Yes | KI | Recovered | [20] |
| 1987 | M | 24 | Elbow | Fixed cutaneous | Student | N | NP | P | P | Yes | KI | Recovered | [20] |
| 1988 | M | 55 | Left index finger and lymph nodes | Lymphocutaneous | Farmer | N | N | P | P | Yes | NR | NR | [21] |
| 1997 | F | 36 | Right knee | Arthritis | Housewife | P | NP | N | N | No | KTZ | Recovered | [22-23] |
| 2000 | F | 56 | Right forearm | Lymphocutaneous | Housewife | N | N | P | P | Yes | Flu | Unchanged | [24] |
| | | | Eye-brow | Fixed cutaneous | | N | N | P | P | Yes | Flu | Recovered | [24] |
| 2007 | M | 23 | Left forearm | Fixed cutaneous | Florist gardener | P | NP | P | P | No | KI | Recovered | [25] |
| 1994 | Male horse | 4 | Left gaskin | Fixed cutaneous | - | P | NP | P | NP | No | KI | Unchanged | [26] |

DE: direct examination, HP: histopathology, C: culture, TD: thermal dimorphism, SL: suspected of leishmaniasis, N: negative, P: positive, NP: not performed, NR: not reported, KTZ: ketoconazole, Flu: fluconazole

sporotrichosis [4, 27, 28]. Efficacy of culture evaluation in the diagnosis of this disease was found to be notable since eight cases out of nine were culture-positive as opposed to the other six cases, which were smear-negative, in the direct examination. In addition, the initial dirty white color of mycelial colony that changes in time from cream color to dark brown at 25°C was considered as another important criterion in the diagnosis of sporotrichosis.

Microscopic examination of the mycelial form was characterized by the delicate, hyaline septate hyphae with oval-shaped conidia arranged in a flower-like pattern in all isolates. Moreover, dimorphic characteristics of the etiologic agents were demonstrated by the conversion of these agents into yeast at 37°C, as well as the identification of the typical oval and cigar-shaped yeast cells.

According to the reported cases reviewed in this study, fixed cutaneous form is the dominant clinical presentation of sporotrichosis in Iran. However, due to the limited number of reports on sporotrichosis cases in Iran, the definite cause for the higher prevalence of fixed cutaneous form is unclear. According to the literature, sporotrichosis most frequently occurs in warm regions of temperate and tropical countries, and it is believed that a significant portion of the population in these areas becomes sensitized to *S. schenckii* without developing any infections. Primary infection in such people is normally restricted to the site of inoculation and is therefore presented as the fixed cutaneous type of infection.

Since certain regions in Iran have favorable climatic conditions for the growth of *Sporothrix*, the prevalence of sporotrichosis could be noticeably higher than the reported rate in this study. In this regard, lack of sufficient research in different areas of the country has led to the inaccurate knowledge of the disease prevalence, as well as the exact environmental sources of the fungus.

Conclusion

Generally, sporotrichosis is not a recognized condition among physicians in Iran, and for this reason, many nodular, ulcerative and

suppurative lesions are misdiagnosed and erroneously treated for leishmaniasis or other bacterial infections. In several cases, this might lead to failure to provide proper treatment and rapid diffusion of the mycosis, which may quickly appear in the form of chronic manifestations.

Author Contributions

In this study, data collection and draft manuscript development were performed by S.M, and F.Z. was in charge of designing, editing and final review of the manuscript.

Conflicts of Interest

None declared.

Financial Disclosure

The authors declare no financial interest regarding the publication of this paper.

References

1. Zaini F, Mehbod ASA, Emami M. Comprehensive Medical Mycology. 3rd ed. Tehran: University of Tehran Press; 2013.
2. Barros MB, Almeida Paes R, Schubach AO. *Sporothrix schenckii* and Sporotrichosis. Clin Microbiol Rev. 2011; 24(4):633-54.
3. Rippon JW. Medical mycology: the pathogenic fungi and the pathogenic actinomycetes. 3rd ed. Eastbourne, UK: W.B. Saunders Co; 1996.
4. Kauffman CA, Pappas PG, Sobel JD, Dismukes WE. Essentials of clinical mycology. New York: Springer; 2011.
5. Romero-Cabello R, Bonifaz A, Romero-Cabello R, Sanchez CJ, Linares Y, Zavala JT, et al. Disseminated sporotrichosis. BMJ Case Rep. 2011; 2011(10):1-4.
6. Kovarik CL, Neyra E, Bustamante B. Evaluation of cats as the source of endemic sporotrichosis in Peru. Med Mycol. 2008; 46(1):53-6.
7. Schubach AO, Schubach TM, Barros MB. Epidemic cat-transmitted sporotrichosis. N Engl J Med. 2005; 353(11):1185-6.
8. Schubach AO, Schubach TM, Barros MB, Wanke B. Cat-transmitted sporotrichosis, Rio de Janeiro, Brazil. Emerg Infect Dis. 2005; 11(12):1952-4.
9. Schubach TM, Schubach A, Okamoto T, Barros MB, Figueiredo FB, Cuzzi T, et al. Evaluation of an epidemic of sporotrichosis in cats: 347 cases (1998-2001). J Am Vet Med Assoc. 2004; 224(10):1623-9.
10. Barros MB, Schubach AO, do Valle AC, Gutierrez Galhardo MC, Conceicao-Silva F, Schubach TM, et al. Cat-transmitted sporotrichosis epidemic in Rio de Janeiro, Brazil: description of a series of cases. Clin Infect Dis. 2004; 38(4):529-35.

11. de Lima Barros MB, de Schubach A, Galhardo MC, Schubach TM, dos Ries RS, Conceicao MJ, et al. Sporotrichosis with widespread cutaneous lesions: report of 24 cases related to transmission by domestic cats in Rio de Janeiro, Brazil. *Int J Dermatol.* 2003; 42(9):677-81.
12. de Lima Barros MB, Schubach TM, Galhardo MC, de Oliveira Schubach A, Monteiro PC, Reis RS, et al. Sporotrichosis: an emergent zoonosis in Rio de Janeiro. *Mem Inst Oswaldo Cruz.* 2001; 96(6):777-9.
13. Fleury RN, Taborda PR, Gupta AK, Fujita MS, Rosa PS, Weckwerth AC, et al. Zoonotic sporotrichosis. Transmission to humans by infected domestic cat scratching: report of four cases in Sao Paulo, Brazil. *Int J Dermatol.* 2001; 40(5):318-22.
14. Marimon R, Cano J, Gene J, Sutton DA, Kawasaki M, Guarro J. *Sporothrix brasiliensis*, *S. globosa*, and *S. mexicana*, three new *Sporothrix* species of clinical interest. *J Clin Microbiol.* 2007; 45(10):3198-206.
15. Marimon R, Gene J, Cano J, Guarro J. *Sporothrix luriei*: a rare fungus from clinical origin. *Med Mycol.* 2008; 46(6):621-5.
16. Madrid H, Cano J, Gene J, Bonifaz A, Toriello C, Guarro J. *Sporothrix globosa*, a pathogenic fungus with widespread geographical distribution. *Rev Iberoam Micol.* 2009; 26(3):218-22.
17. Oliveira MM, Almeida-Paes R, Gutierrez-Galhardo MC, Zancope-Oliveira RM. Molecular identification of the *Sporothrix schenckii* complex. *Rev Iberoam Micol.* 2014; 31(1):2-6.
18. Zaini F. Sporotrichosis in Iran: First report of isolation of *Sporothrix schenckii* from clinical material. *Acta Med Iran.* 1984; 26(1-4):33-9.
19. Nematian J. Investigation and study of subcutaneous fungal agents. School of Public Health, Tehran University of Medical Sciences, Iran; 1984.
20. Dehghan P. Investigation of sporotrichosis in patients with suspected lesions of cutaneous leishmaniasis. School of Public Health, Tehran University of Medical Sciences, Iran; 1987.
21. Moghadami M, Adimi P. First report of lymphocutaneous sporotrichosis in Iran. *J Res Med Sci.* 1988; 12(1-2): 62-57.
22. Asadi MA, Houshyar H, Soltani SAK, Dorougar A. First report of Sporotrichal arthritis in Iran. *J Kashan Uni Med Sci.* 1998; 2(1):99-106.
23. Sharif AR, Sharifi H, Asadi MA, Khorshidi A, Saffari M. The effect of Ketoconazol on the treatment of first case of fungal arthritis in Iran. *J Kashan Uni Med Sci.* 2005; 8(4):69-72.
24. Ghodsi SZ, Shams S, Naraghi Z, Daneshpazhooh M, Akhyani M, Arad S, et al. Case Report. An unusual case of cutaneous sporotrichosis and its response to weekly fluconazole. *Mycoses.* 2000; 43(1-2):75-7.
25. Kazemi A, Razi A. Sporotrichosis in Iran. *Rev Iberoam Micol.* 2007; 24(1):38-40.
26. Naadalian MG, Dalir B, Khosravi A. The first report of sporotrichosis in horse in around Tehran. *J Veter Res.* 1997; 51(3-4):91-5.
27. Richadson MD, Warnock DW. *Fungal Infection: Diagnosis and Management.* 3rd ed. UK: John Wiley & Sons; 2003.
28. Anassie EJ, McGinnis MR, Pfaller MA. *Churchill Livingston.* Philadelphia: Clinical Mycology; 2003.