

## Case Report

## Osteomyelitis and lung abscess due to *Aspergillus fumigatus* in a chronic granulomatous disease patient

Mamishi S<sup>1</sup>, Zomorodian K<sup>2</sup>, Saadat F<sup>3</sup>, Jalali SZ<sup>4</sup>, Geramishoar M<sup>5</sup>

<sup>1</sup> Department of Infectious Diseases, Tehran University of Medical Sciences, Tehran, Iran

<sup>2</sup> Basic Sciences in Infectious Diseases Research Center, Department of Medical Mycology and Parasitology, School of Medicine, Shiraz University of Medical Sciences, Shiraz, Iran

<sup>3</sup> Faculty of Medicine, Guilan University of Medical Sciences, Rasht, Iran

<sup>4</sup> Department of Pediatrics, Faculty of Medicine, Guilan University of Medical Sciences, Rasht, Iran

<sup>5</sup> Department of Medical Mycology and Parasitology, School of Public Health, Tehran University of Medical Sciences, Tehran, Iran

\*Corresponding author: Seyedeh Zohreh Jalali, Department of pediatrics, Faculty of Medicine, Guilan University of Medical Sciences, Rasht, Iran .Email: z\_jalali@gums.ac.ir

(Received: 18 September 2016; Revised: 28 December 2016; Accepted: 16 January 2016)

### Abstract

**Background and Purpose:** Chronic granulomatous disease (CGD) is an inherited disorder of the nicotinamide adenine dinucleotide phosphate (NADPH) oxidase complex. This disorder results in recurrent life-threatening bacterial and fungal infections. *Aspergillus* species are the most common fungal infections in these patients.

**Case Report:** Herein, we present a case of fungal infection in a girl with CGD. We confirmed aspergillosis through the positive microscopic and macroscopic examinations, as well as radiology results. Invasive aspergillosis in this patient with pneumonia, lung abscess, and osteomyelitis of the ribs was not initially treated with amphotericin B (Am B) and recombinant interferon-gamma.

**Conclusion:** Among infectious diseases ,fungal infections ,in particular aspergillosis ,remain a serious problem in CGD patients. Considering poor clinical response and deficient immune system, rapid diagnosis of fungal infection and optimizing the treatment of these patients are recommended.

**Keywords:** Antifungal agents, *Aspergillus*, Chronic granulomatous disease

#### ➤ How to cite this paper:

Mamishi S, Zomorodian K, Saadat F, Jalali SZ, Geramishoar M. Osteomyelitis and lung abscess due to *Aspergillus fumigatus* in a chronic granulomatous disease patient. Curr Med Mycol. 2016; 2(3): 37-41. DOI: [10.18869/acadpub.cmm.2.3.37](https://doi.org/10.18869/acadpub.cmm.2.3.37)

### Introduction

Chronic granulomatous disease (CGD) is a disorder causing defective superoxide generation and intracellular killing. Patients usually present recurrent life-threatening infections, chronic granulomas, and poor wound healing. CGD can be inherited in two forms of autosomal recessive and X-linked. The former is much more common, accounting for about 70% of the cases [1].

Recurrent fungal or bacterial infections and inflammatory complications are the main characteristics of this disease. In a recent cohort study of common severe infections in CGD patients, the incidence of fungal infections in the patients was estimated to be as high as 20%. *Aspergillus* species with the incidence rate of 2.6 cases per 100 person-years were found to be the most common pathogens causing infection in CGD patients [2]. Of *Aspergillus* species, *A. fumigatus* and *A. nidulans* are the most commonly isolated species [3].

Early diagnosis and prophylactic antimicrobial therapy along with rapid treatment of the established

infections with administration of  $\gamma$ -interferon (INF- $\gamma$ ) plus other antifungal agents in the case of fungal infections are reported to be helpful in the treatment of these patients [4, 5]. Although, the occurrence of severe bacterial infections in CGD patients has remarkably reduced by the routine prophylactic antibacterial use [6], fungal infections with high mortality rate remain a serious problem in these patients [7]. Another crisis in the management of fungal infections in these patients is the occurrence of antifungal resistance and failure of treatment with antifungal agents [8].

### Case Report

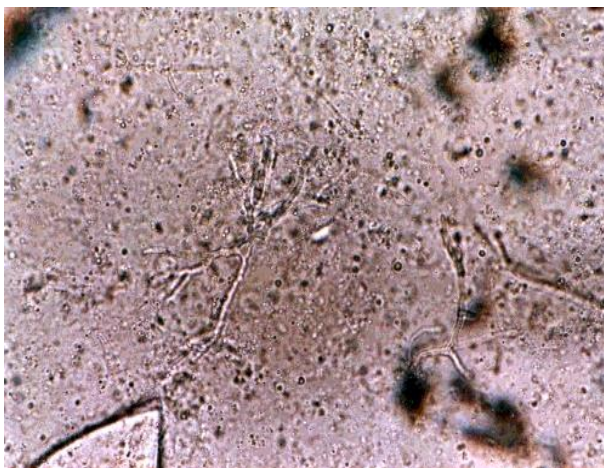
In the current study, we present the case of a 4.5 year-old girl who was admitted to Children Medical Center (CMC) in Tehran, Iran. She was the only child of consanguineous parents who revealed no history of primary immunodeficiency. The first manifestations of her present illness were fever, productive cough, and shoulder pain, which had begun 25 days prior to admission. Her past medical history was significant

for suffering from suppurative lymphadenitis of axillary region at four months of age followed by two episodes of bacterial infections, including salmonella osteomyelitis and tuberculosis at the ages of one and two, respectively.

Laboratory test results were all normal, except for elevated sedimentation rate (ESR=70). Based on her history and positive nitro blue tetrazolium (NBT) test, diagnosis of CGD was confirmed. Chest radiography revealed several consolidations in the apex and third segment of the right lung, as well as posterior segment of the left lung suggesting bacterial pneumonia or tuberculosis. Considering three times negative results of tuberculosis (TB) test, she received cotrimoxazole (20 mg/kg, i.v.) with suspicion of bacterial pneumonia.

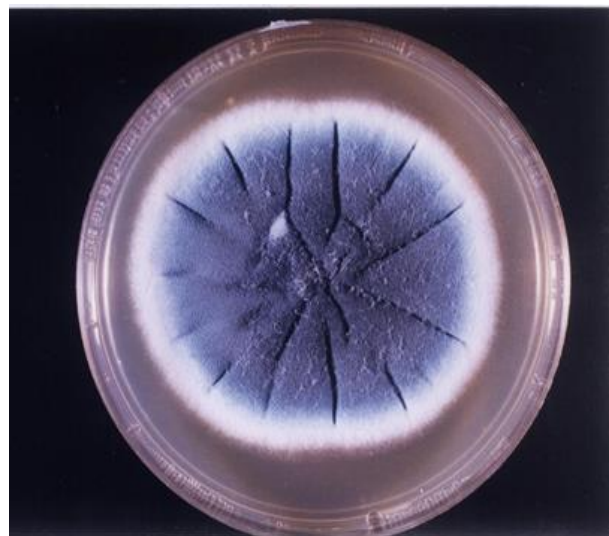
Upon her readmission to the hospital one month later, the patient's chief complaint was severe dry cough. Laboratory test results showed leukocytosis. Direct microscopy and culture of bronchoalveolar lavage (BAL) sample were negative for both fungal elements and TB. In addition, hot-start PCR with specific primers and fluorescent probe yielded negative results. Although the patient was placed on various antibacterial agents (amikacin, cephalothin, and cotrimoxazole) plus INF- $\gamma$  (50  $\mu\text{g}/\text{m}^2$ ), her chest X-ray still showed scattering from previous pneumonia, for which she received cotrimoxazole (5mg/kg/day) and INF- $\gamma$  three times a week.

After eight days, computerized tomography (CT) scan of the chest and abdomen was performed and revealed large abscess in the right lung and osteomyelitis on the 9<sup>th</sup> and 10<sup>th</sup> posterior right ribs. After drainage of the abscess, a sample was sent to the Mycology and Parasitology Department. The microscopic examination indicated branched, septate hyphae with dichotomous angles suggesting *Aspergillus* species (Figure 1). The



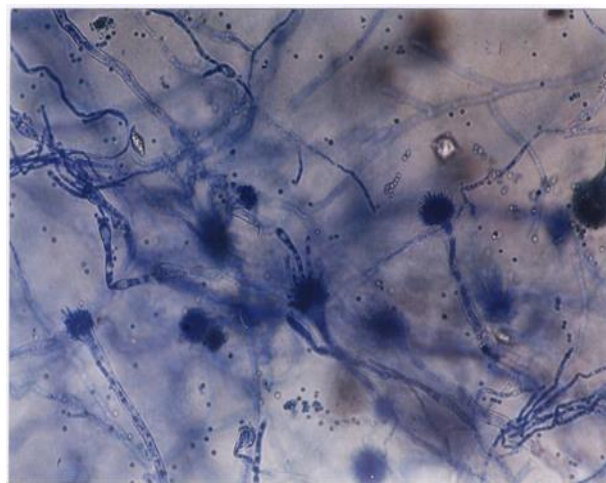
**Figure 1.** Branched, septate hyphae with dichotomous angles

specimen was also cultured on different culture media and the bluish green colonies grew rapidly (Figure 2).



**Figure 2.** Rapidly growing bluish green colonies of *Aspergillus fumigatus* complex isolated from drainage of abscess

Cellophane tape preparations and slide cultures demonstrated smooth-walled conidiophores with swollen flask shaped vesicle covered by single row of phialides on the upper half of the vesicle (Figure 3). Based on these microscopic and macroscopic findings, *Aspergillus fumigatus* complex was determined as the causative agent in this case. Following diagnosis, administration of amphotericin B (1 mg/kg/day) and INF- $\gamma$  (50  $\mu\text{g}/\text{m}^2$  three times weekly) was initiated. After three weeks of treatment, the patient's condition improved. In her subsequent CT scan, no further progress of the

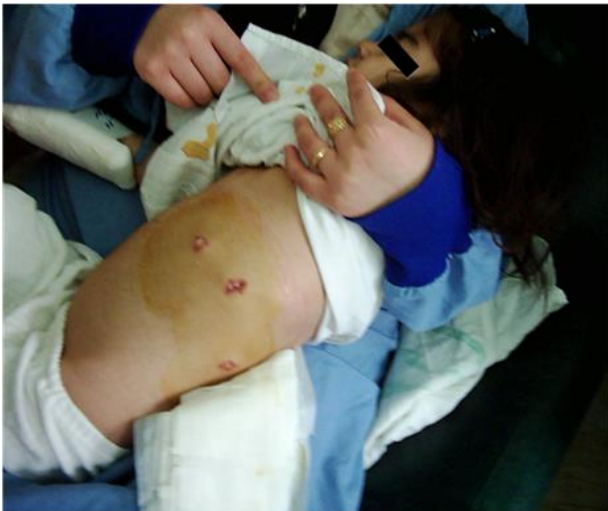

**Figure 3.** A microscopic view of *Aspergillus fumigatus* complex showing smooth walled conidiophores with swollen flask shaped vesicle covered by single row of phialides on the upper half of the vesicle

abdominal masses was observed. The parenteral antifungal treatment was then switched to oral itraconazole, INF- $\gamma$ , and cotrimoxazole as long-term prophylaxis.

Two weeks later, cutaneous exudative abscess on the left side of her chest was observed (Figure 4). Based on isolation of *Aspergillus fumigatus* from culture of abscess, oral antifungal therapy was switched to intravenous deoxycholate am B (12 mg/day). After two weeks of treatment, the patient showed no clinical or laboratory improvement. A new thoraco-abdominal X-ray revealed progressive bilateral pulmonary infiltrates and osteolytic lesions of the left third rib. The affected ribs and surrounding infected soft tissues were excised.

Despite two weeks of treatment with am B, 5-fluorocytosine, cotrimoxazole, and INF- $\gamma$ , destructive lesions in the posterior arc of the right third rib, as well as anterior arc of the 5<sup>th</sup>, 6<sup>th</sup>, 7<sup>th</sup>, and 8<sup>th</sup> left ribs were seen in the chest X-ray. These findings were indicative of diffuse fungal osteomyelitis. Thus, the patient was transferred to the pediatric intensive care unit. Intubation was performed and mechanical ventilation was started. Regardless of antifungal and surgical therapy, the patient expired due to disseminated aspergillosis.



**Figure 4.** Subcutaneous swelling and granuloma formation in the left upper quadrant

## Discussion

Rapid diagnosis and proper treatment of invasive fungal infections is still a challenging problem in CGD patients. In most of the cases, clinical manifestations are not specific. In these patients, lungs are one of the most common sites of infection. In a report from the US Registry, the majority of CGD patients suffer from at least one

episode of pneumonia followed by subcutaneous or liver abscesses, osteomyelitis, fungemia, or meningitis, which is very similar to clinical course of infection in our patient [9]. Moreover, osteomyelitis is reported in 25% of CGD patients, which similar to our case, most commonly initiates from dissemination of a pulmonary infection or an abscess in the lung [9, 10].

Generally, *Aspergillus* spp. are responsible for more than two-third of all fungal infections and one-fifth of all osteomyelitis cases in CGD patients [10]. Similar to the majority of previous reports [5, 10], the causative agent of invasive aspergillosis (IA) in this case was identified as *A. fumigatus* complex.

Use of sensitive methods such as detection of galactomannan or molecular-based techniques is highly recommended for rapid diagnosis of IA in CGD patients and prevention of dissemination. However, microscopic identification of fungal elements in tissue along with positive fungal culture is still regarded as the gold standard for identification of IA. Antifungal therapy should be initiated once there is a clinical suspicion of IA. Unfortunately, more than one-third of CGD patients with *Aspergillus* osteomyelitis [37%] do not respond to treatment [11]. It was reported that debridement of the site of infection might be successful [12]. In IA, the fungi usually invade the blood vessels and penetrate into tissues [13]. Regardless of the debridement of the infected sites, our patients did not show a proper response.

In spite of antifungal therapy, the mortality rate of aspergillosis in patients is still high [10, 14]. Amphotericin B is the first line of antifungals that is commonly used against invasive fungal infections and has shown to be clinically effective. Resistance to am B is reported in about 10% of clinical isolates of *Aspergillus* [15] and is associated with fetal infections in about 22% of the patients [14]. Such a poor outcome might be due to either resistance of the isolate to drug or poor dissemination of the drug into infected sites [13, 14]. Unfortunately, few choices are available for treatment of IA caused by am B-resistant strains. New generation of azoles and echinocandins might be useful in this regard. However, based on a recent report from Iran, the number of azole-resistant *A. fumigatus* strains against itraconazole increased significantly from 3% to 6% [16]. Some studies indicated that mutations might confer resistance to individual azoles, rather than to the whole class [17]. Novel triazoles also demonstrated a promising effect against IA. Voriconazole, a triazole antifungal

medication, is successfully used in the treatment of invasive fungal infections in CGD patients [18]. However, in resource-limited settings or when voriconazole cannot be administered, am B is recommended as an appropriate option for initial and salvage therapy [18].

It was previously demonstrated that the addition of flucytosine to am B might decrease the dose of amphotericin B and enhance patient response. This is the reason it was added to our patient's regimen [19, 20]. Considering poor clinical response to am B or other antifungals in some strains of *Aspergillus*, performing antifungal susceptibility testing in CGD patient is highly recommended.

### Acknowledgments

We would like to thank the patient and nurses who participated in this study.

### Author's contribution

All the authors' contributed equally to this study.

### Conflicts of interest

The authors declare that they have no competing financial interests in relation to the work described.

### Financial disclosure

This study was supported by Tehran University of Medical Sciences.

### References

1. Roos D, de Boer M, Kuribayashi F, Meischl C, Weening RS, Segal AW, et al. Mutations in the X-linked and autosomal recessive forms of chronic granulomatous disease. *Blood*. 1996; 87(5): 1663–81.
2. Marciano BE, Spalding C, Fitzgerald A, Mann D, Brown T, Osgood S, et al. Common severe infections in chronic granulomatous disease. *Clin Infect Dis*. 2015; 60 (8):1176-83.
3. Henriët S, Verweij PE, Holland SM, Warris A. Invasive fungal infections in patients with chronic granulomatous disease. *Adv Exp Med Biol*. 2013; 764: 27-55.
4. Bieloraï B, Toren A, Wolach B, Mandel M, Golan H, Neumann Y, et al. Successful treatment of invasive aspergillosis in chronic granulomatous disease by granulocyte transfusions followed by peripheral blood stem cell transplantation. *Bone Marrow Transplant*. 2000; 26(9):1025-8.
5. Mamishi S, Zomorodian K, Saadat F, Gerami-Shoar M, Tarazooie B, Siadati SA. A case of invasive aspergillosis in CGD patient successfully treated with amphotericin B and INF-gamma. *Ann Clin Microbiol Antimicrob*. 2005; 4:4.
6. Liese J, Kloos S, Jendrossek V, Petropoulou T, Wintergerst U, Notheis G, et al. Long-term follow-up and outcome of 39 patients with chronic granulomatous disease. *J Pediatr*. 2000; 137(5):687-93.
7. Segal BH, Barnhart LA, Anderson VL, Walsh TJ, Malech HL, Holland SM. Posaconazole as salvage therapy in patients with chronic granulomatous disease and invasive filamentous fungal infection. *Clin Infect Dis*. 2005 ; 40 (11):1684-8.
8. Sabino R, Carolino E, Veríssimo C, Martinez M, Clemons KV, Stevens DA. Antifungal susceptibility of 175 *Aspergillus* isolates from various clinical and environmental sources. *Med Mycol*. 2016; 54 (7):740-56.
9. Winkelstein JA, Marino MC, Johnston RB Jr, Boyle J, Curnutte J, Gallin JI, et al. Chronic granulomatous disease. Report on a national registry of 368 patients. *Medicine (Baltimore)*. 2000; 79(3):155-69.
10. Mamishi S, Parvaneh N, Salavati A, Abdollahzadeh S, Yeganeh M. Invasive aspergillosis in chronic granulomatous disease: report of 7 cases. *Eur J Pediatr*. 2007; 166(1):83-4.
11. Dotis J, Roilides E. Osteomyelitis due to *Aspergillus* species in chronic granulomatous disease: an update of the literature. *Mycoses*. 2011; 54(6):e686-96.
12. Segal BH, De Carlo ES, Kwon-Chung KJ, Malech HL, Gallin JI, Holland SM. *Aspergillus nidulans* infection in chronic granulomatous disease. *Medicine*. 1998; 77(5):345-54.
13. Paterson PJ, Seaton S, Prentice HG, Kibbler CC. Treatment failure in invasive aspergillosis: susceptibility of deep tissue isolates following treatment with amphotericin B. *J Antimicrob Chemother*. 2003; 52(5):873-6.
14. Hadrich I, Makni F, Neji S, Cheikhrouhou F, Bellaaj H, Elloumi M, et al. Amphotericin B in vitro resistance is associated with fatal *Aspergillus flavus* infection. *Med Mycol*. 2012; 50(8):829-34.
15. Al-Wathiqi F, Ahmad S, Khan Z. Molecular identification and antifungal susceptibility profile of *Aspergillus flavus* isolates recovered from clinical specimens in Kuwait. *BMC Infect Dis*. 2013; 13:126.
16. Nabili M, Shokohi T, Moazeni M, Khodavaisy S, Aliyali M, Badiëe P, et al. High prevalence of clinical and environmental triazole-resistant *Aspergillus fumigatus* in Iran: is it a challenging issue? *J Med Microbiol*. 2016; 65(6):468-75.
17. Mann PA, Parmegiani RM, Wei SQ, Mendrick CA, Li X, Loebenberg D, et al. Mutations in *Aspergillus fumigatus* resulting in reduced susceptibility to posaconazole appear to be restricted to a single amino acid in the cytochrome P450 14alpha-demethylase. *Antimicrob Agents Chemother*. 2003; 47(2):577-81.
18. Patterson TF, Thompson GR 3rd, Denning DW, Fishman JA, Hadley S, Herbrecht R, et al. Executive summary: practice guidelines for the diagnosis and management of *Aspergillosis*: 2016 update by the infectious diseases society of America. *Clin Infect Dis*.

- 2016; 63(4):433-42.
19. Codish SD, Tobias JS, Hannigan M. Combined amphotericin B-flucytosine therapy in *Aspergillus* pneumonia. JAMA. 1979; 241(22):2418-9.
  20. Saral R. *Candida* and *Aspergillus* infections in immunocompromised patients: an overview. Rev Infect Dis. 1991; 13(3):487-92.